



Dr Zandré Botha (Ph D Alt. Med)
18 Wildebees Street
Rant en Dal
1751
Gauteng
South Africa
Practice No: LC-HPD083108
Office nr: 081 526 6005

To Whom it may concern

Herewith report on the findings of patients that had the Pfizer and Johnson & Johnson Vaccine.

My intention is to seek answers and to the best of my ability to do no harm and to share knowledge with my patients regarding their health and wellbeing.

I have seen over fifty patients from June 2021 who had the vaccine. All came to see me seeking help because they have significant health issues, since they had the Covid vaccine.

Some of the symptoms, in no particular order that I have observed:

- Severe headache lasting more than eight weeks
- Severe nerve pain lasting more than eight weeks
- Paranoia
- Dizziness
- Hypertension (with no prior history)
- Blood Clots
- Quick onset thrombosis
- Irritability
- Pain that won't subside at injection site
- Epilepsy
- Fatigue
- Shortness of breath
- Multiple heart attacks

I performed my blood analysis, using the Neogenesis System NGS - Life Blood



Dr Zandr  Botha (Ph D Alt. Med)
18 Wildebees Street
Rant en Dal
1751
Gauteng
South Africa
Practice No: LC-HPD083108
Office nr: 081 526 6005

Analysis 20/20 Microscope. Using light and dark field microscopy. This microscope is considered the gold standard and one of the best microscopes suggested to do bright field and dark field analysis:

Abnormalities observed in the blood of vaccinated patients:

- **Severe rouleau**, where the red blood cells form a chainlike string. All the vaccinated people have very tightly stacked red blood cells, a more serious form of rouleau suggestive of a patient with a chronic degenerative disease or advanced endobiosis and advanced colon, liver and small intestine damage. Rouleau can be found in unvaccinated blood too; however I only see the advanced stacking in vaccinated blood. The only other time I have seen it was in a HIV or cancer patient.
- **Red blood cell rings**, indicating high cortisol levels explaining the paranoia and anxiety and difficulty breathing. The pituitary gland may be affected.
- **Schistocytes**, fragmented red blood cells, most related to cardiac and vessel abnormalities as well as diseases of the small blood vessels with disturbance of the microcirculation. Ingestion of toxins. Damaged spleen. Microvascular disturbances, blocking of small arteries in the heart. Can also be indicative of pulmonary emboli, endocarditic, thrombotic activity. D-Dimer test can be done.
- **Disrupted white blood cells**. This is associated with compromised immunity.
- **Empty white blood cells**. Associated with autoimmune conditions. Severe parasitic burden.
- **Fibrin**. Indicative of increased risk of thrombosis.



Dr Zandr  Botha (Ph D Alt. Med)
18 Wildebees Street
Rant en Dal
1751
Gauteng
South Africa
Practice No: LC-HPD083108
Office nr: 081 526 6005

- **Crystals named protoplasts:** Low tissue oxygenation, compromised immunity.
- **Black Crystals:** Normally seen only in patients that use recreational drugs or high dosages prescription drugs that are not prescribed but are used like a drug.
- **Unidentified crystals and artifacts:** Artifacts are a term we use when we find an object that is inorganic. When observing patients that have not had the vaccine, I might see one artifact in 10 patients. In the vaccination I see unidentified artifacts with each one without fail. Surely it can't be a coincidence? I also saw dark crystals that I have not seen before and couldn't identify.

Note: Based on patient feedback, if they had a previous existing condition, the symptoms are worse after the vaccine. Some show little symptoms, writing it off to fatigue and stress, but the blood all look the same, regardless of the severity of symptoms, as explained above in my observations.

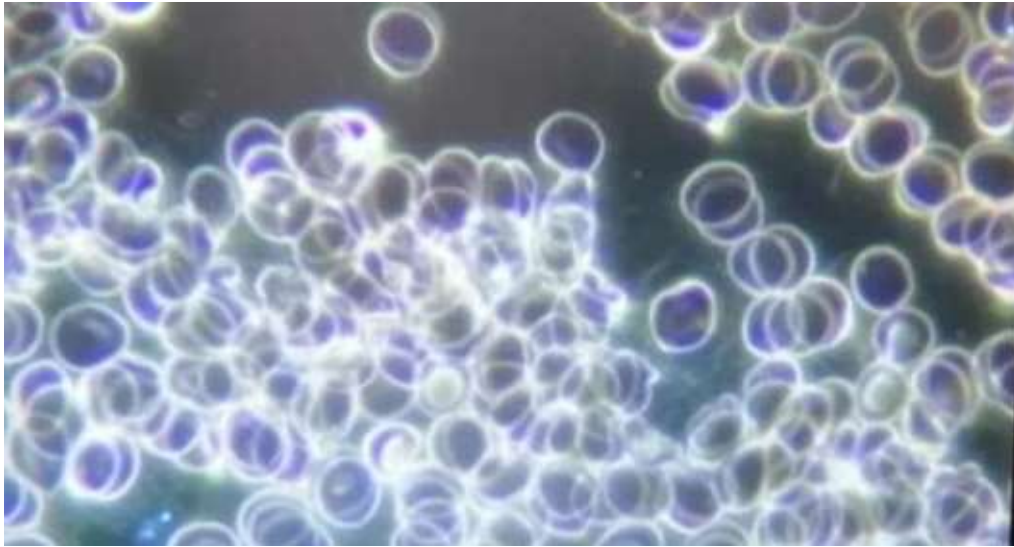
The saying, a picture is worth a thousand words, has never been more relevant.

Herewith pictures of a patient that I have treated before and after the vaccine

Patient Information:

- **Female**
- **Born 1963 (58 years old)**
- **Reason for visit: Overall health, stress and weight loss**

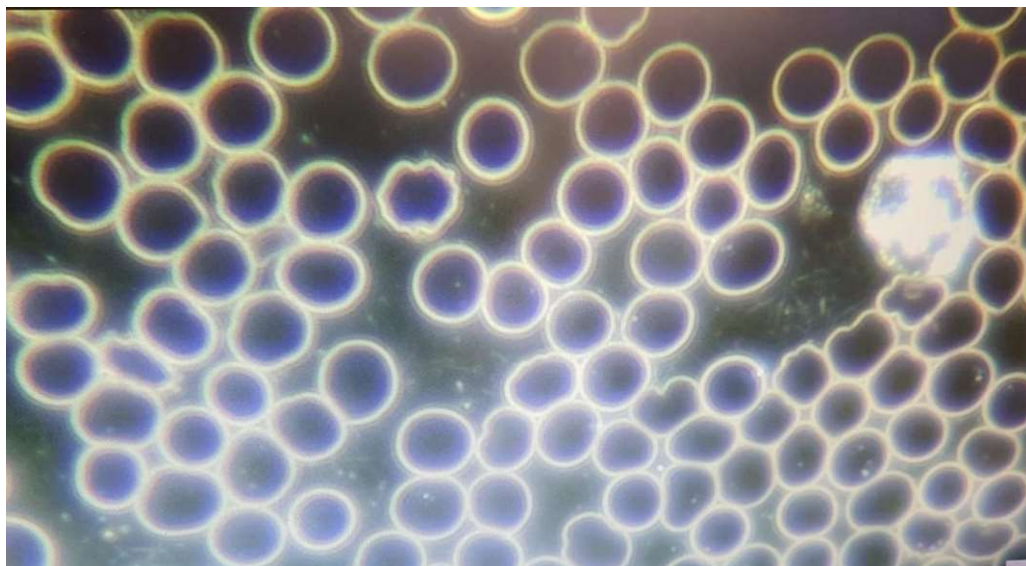
Picture of blood first consultation BEFORE vaccine 14 October 2020:



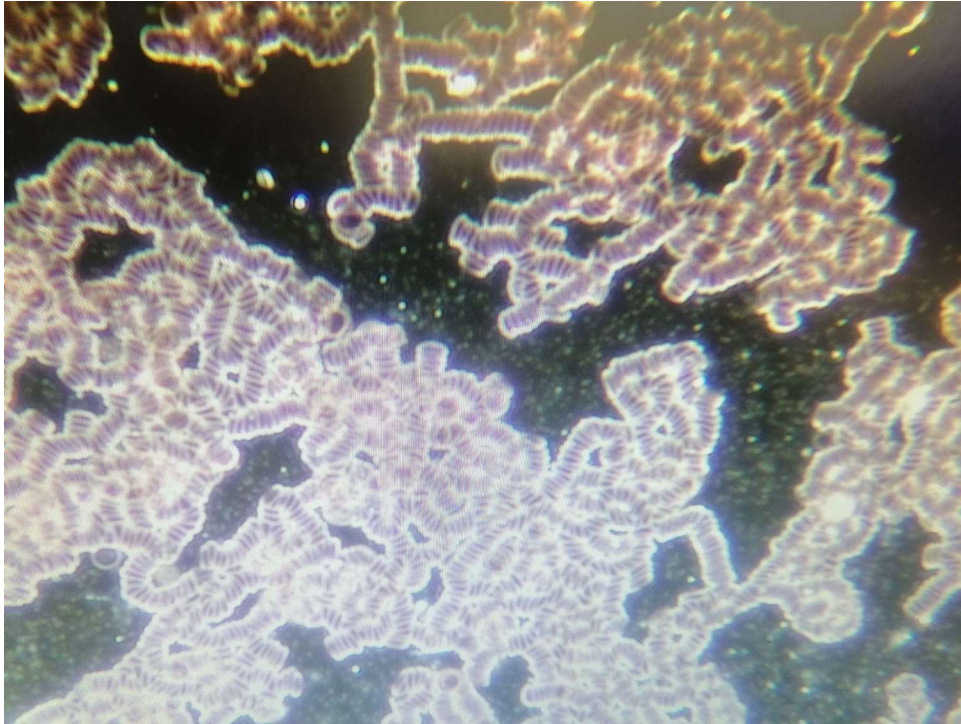
Some normal red blood cells and common rouleau seen. Two target cells showing a very slight oxygen transfer dysfunction.

Therapy suggested: Healthy eating habits, Ozone therapy, Molecular hydroge

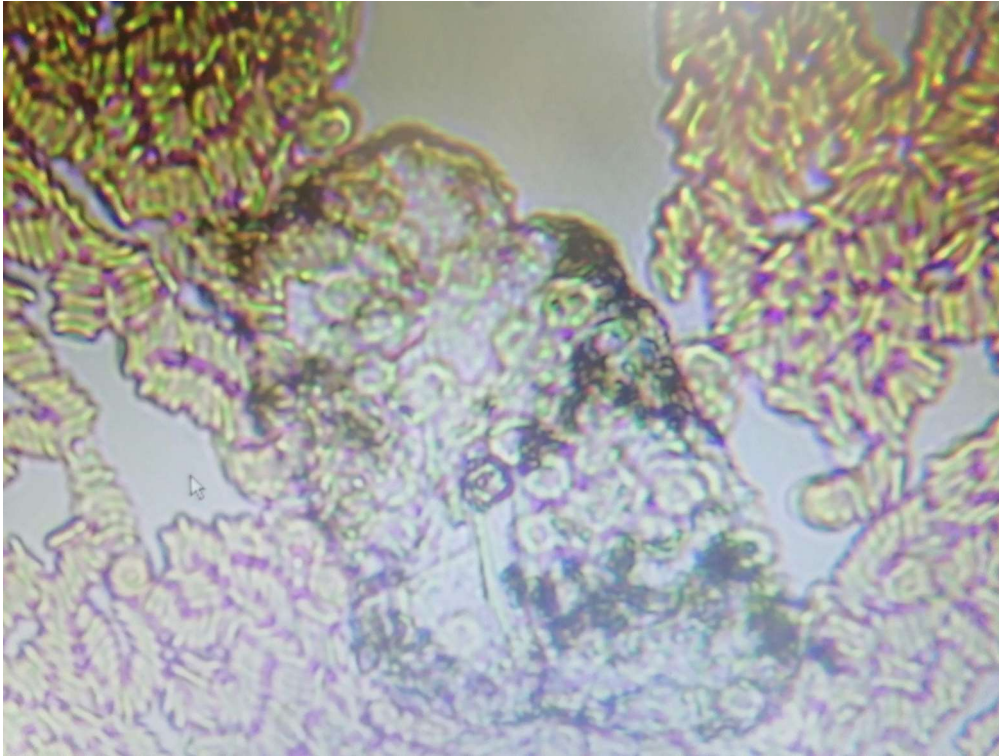
Picture of blood after therapy and BEFORE VACCINE, lifestyle change and weight loss of 18kg .14 Feb 2021.



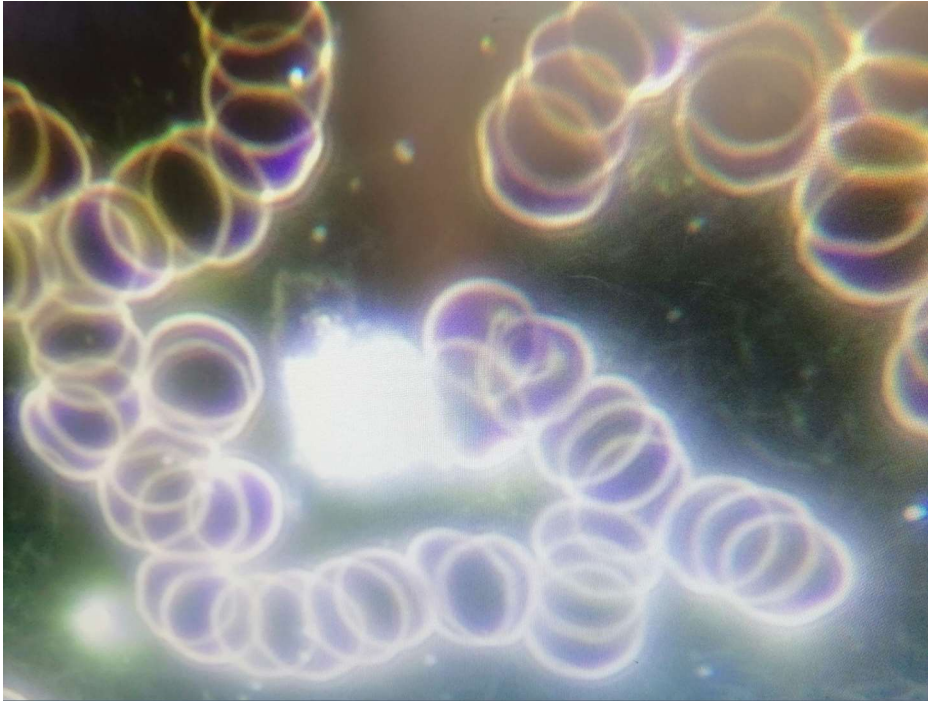
Pictures of patients blood **AFTER VACCINE** 20 September 2021



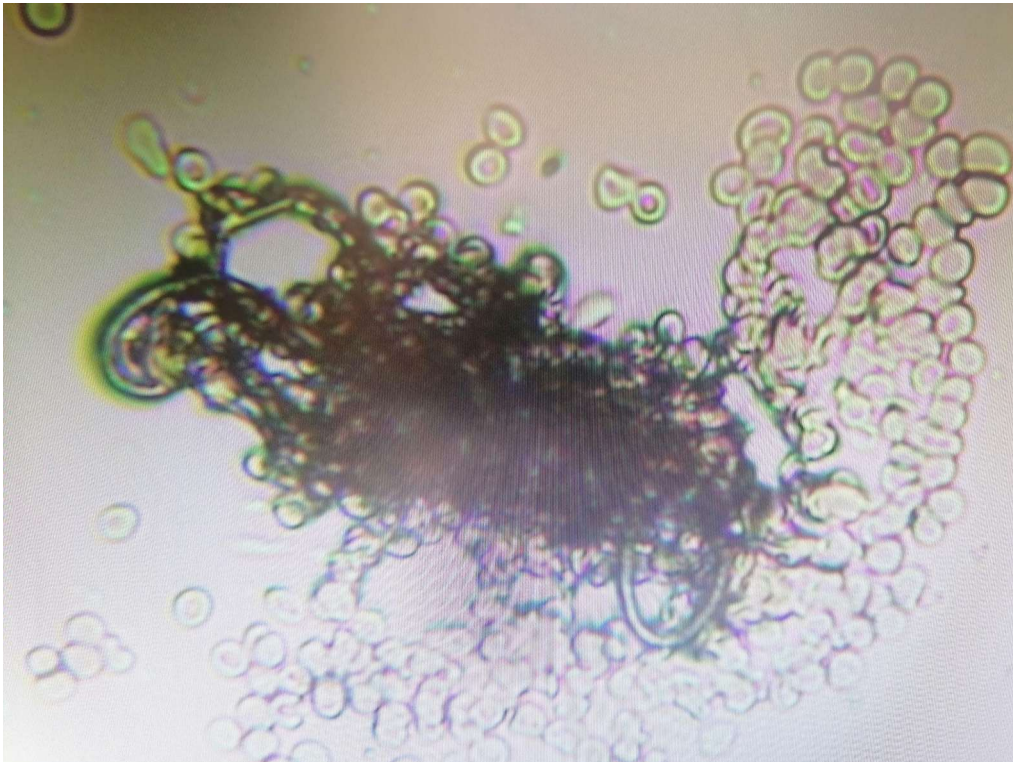
Stacked rouleau, white reflective particles spotted in the plasma, very low oxygen in the blood, patient now complaining of shortness of breath and fatigue, gained 5kg. Saturation between 89 and 91 on the oximeter.



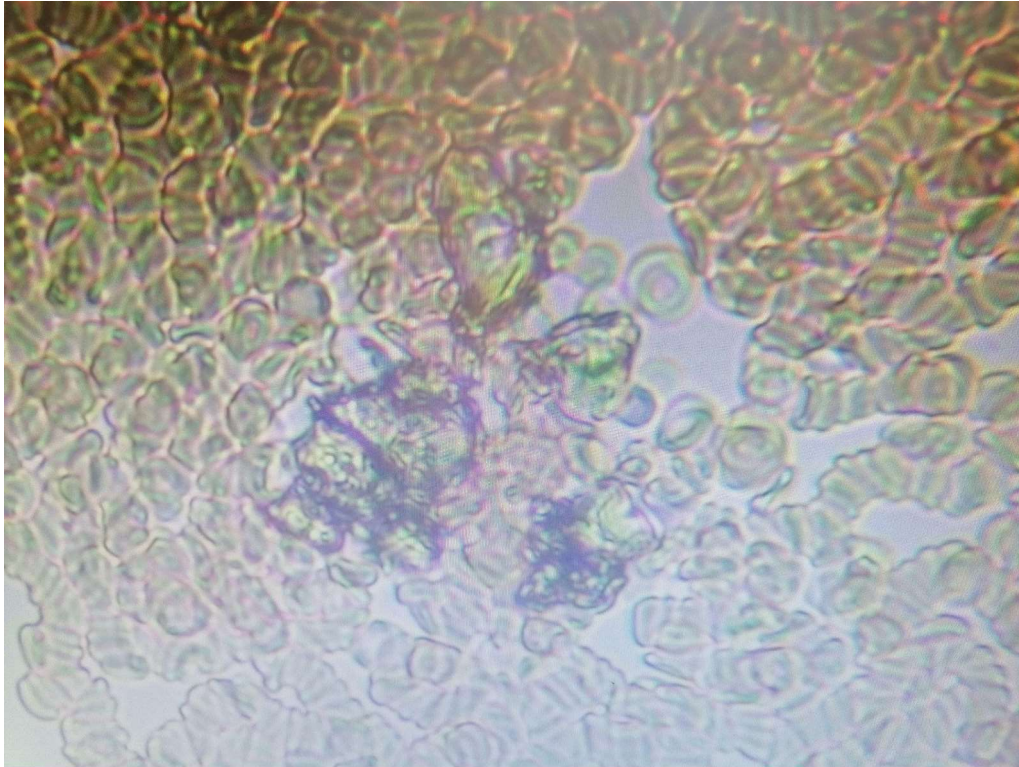
Unidentified crystal similar to a protoplast but not 100% sure. This picture was taken in light field where the dark background is not visible. Stacked rouleau, the most severe and serious form of rouleau, seen in all patients that had the vaccination.



Non viable white blood cell




Unidentified artifact, or substance. Again consistent with every vaccinated patient.

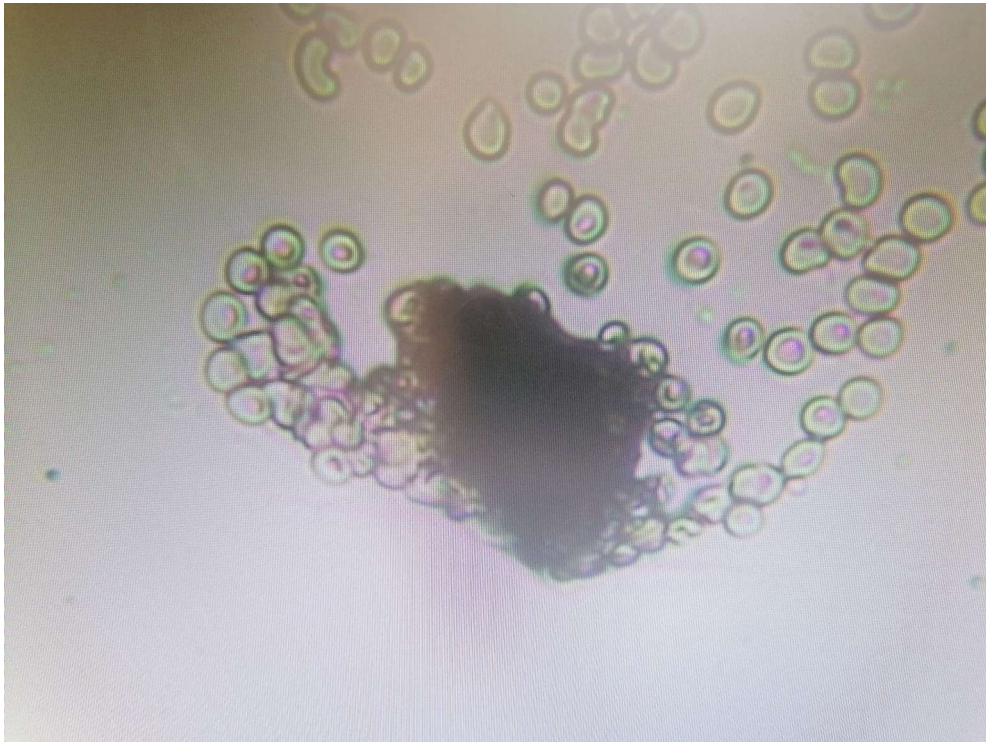

Unidentified crystal like structures consistent with every vaccinated patient.

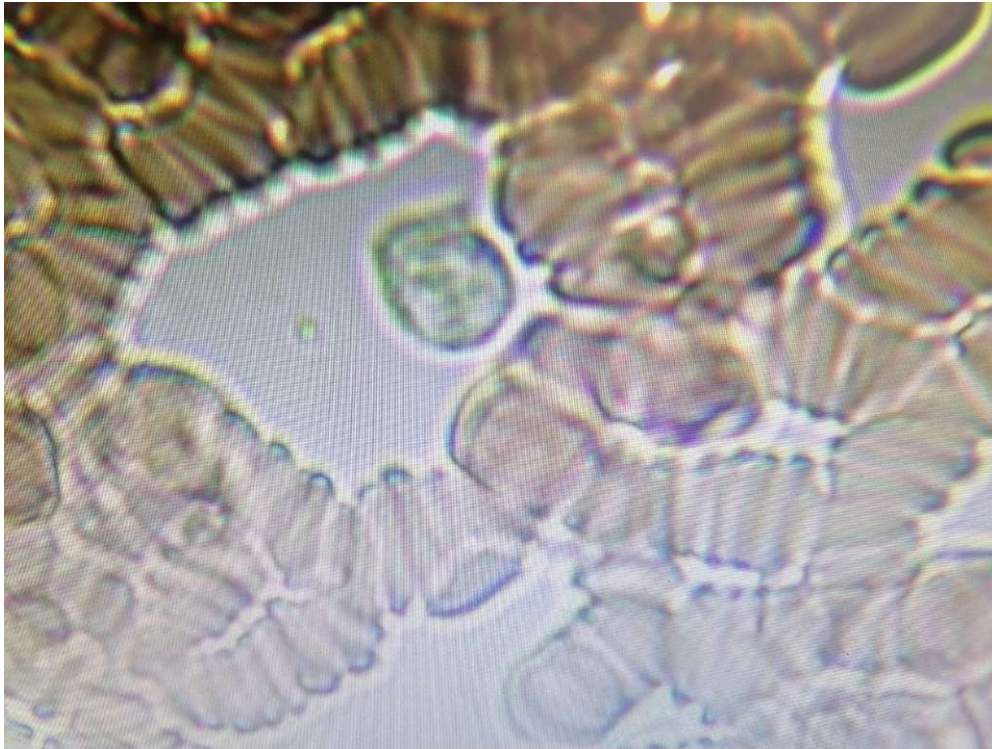1. Pictures of some of the **vaccinated** patients I have seen in the last month all showing similar findings and abnormalities:



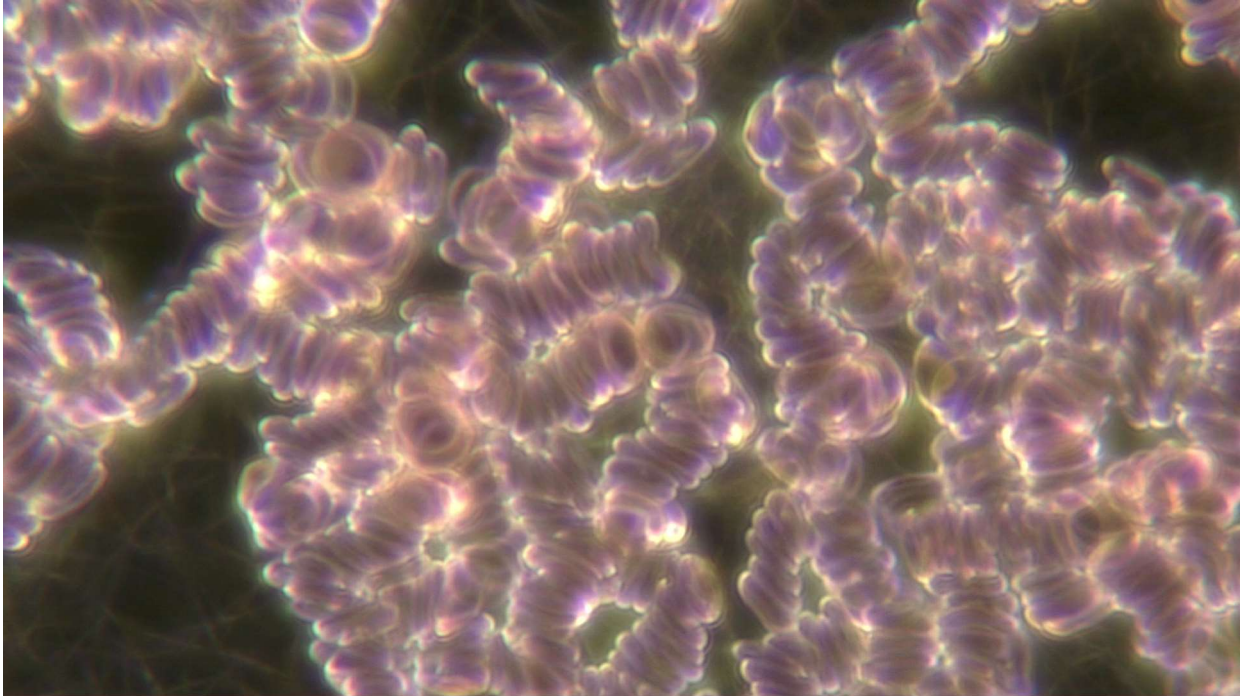
2. Abnormal and unidentified crystal or substance with stacked RBC seen in vaccinated patients



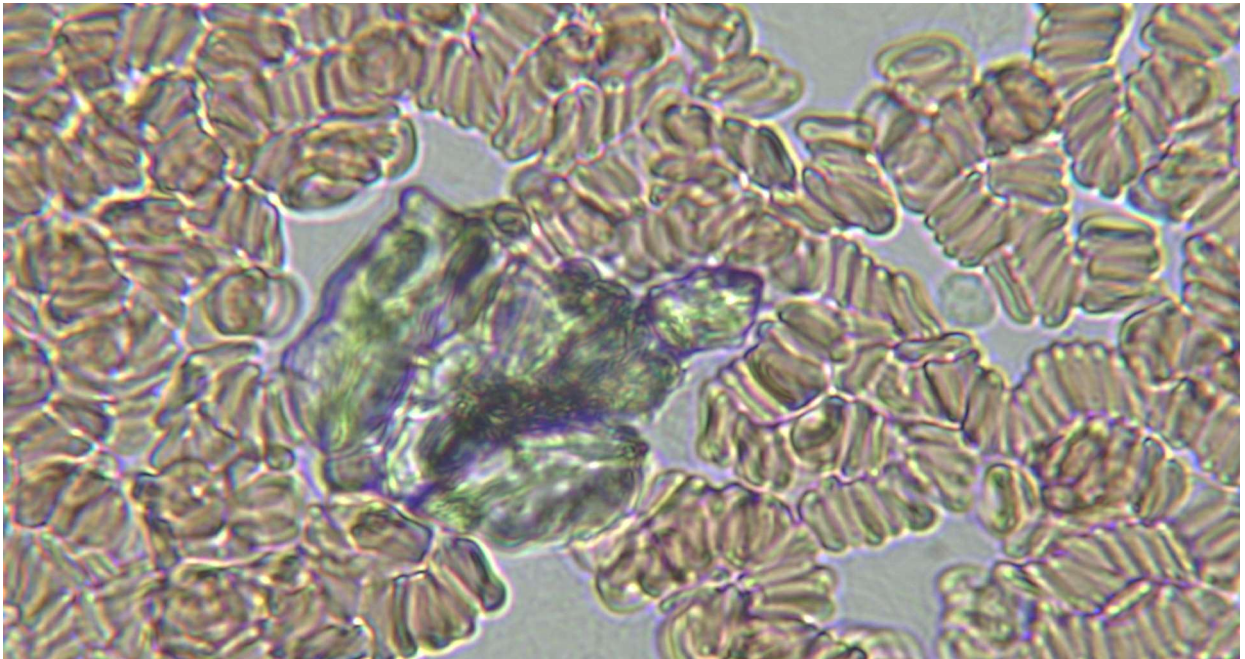
3. Stacked rouleau and non viable white blood cell



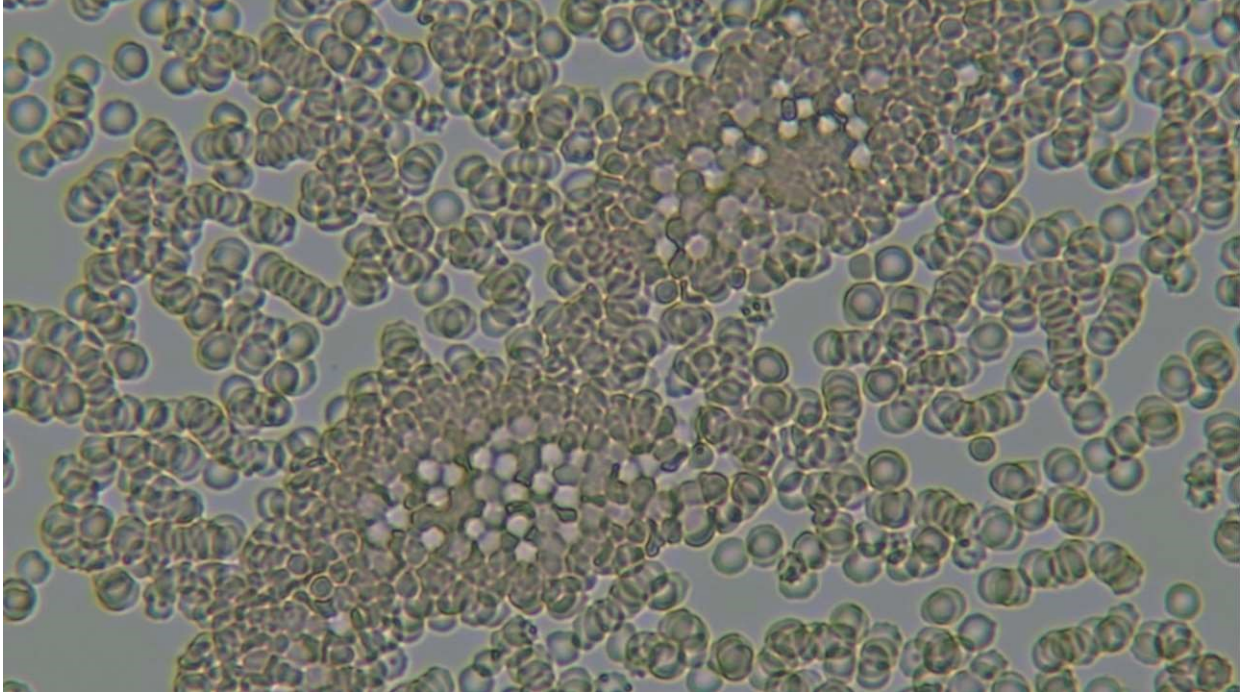
4. Severe rouleau, where the red blood cells form a chainlike string. All the vaccinated people have very tightly stacked red blood cells, a more serious form of rouleau suggestive of a patient with a chronic degenerative disease or advanced endobiosis (parasitic activity) and advanced colon, liver and small intestine damage. 1600 x magnification



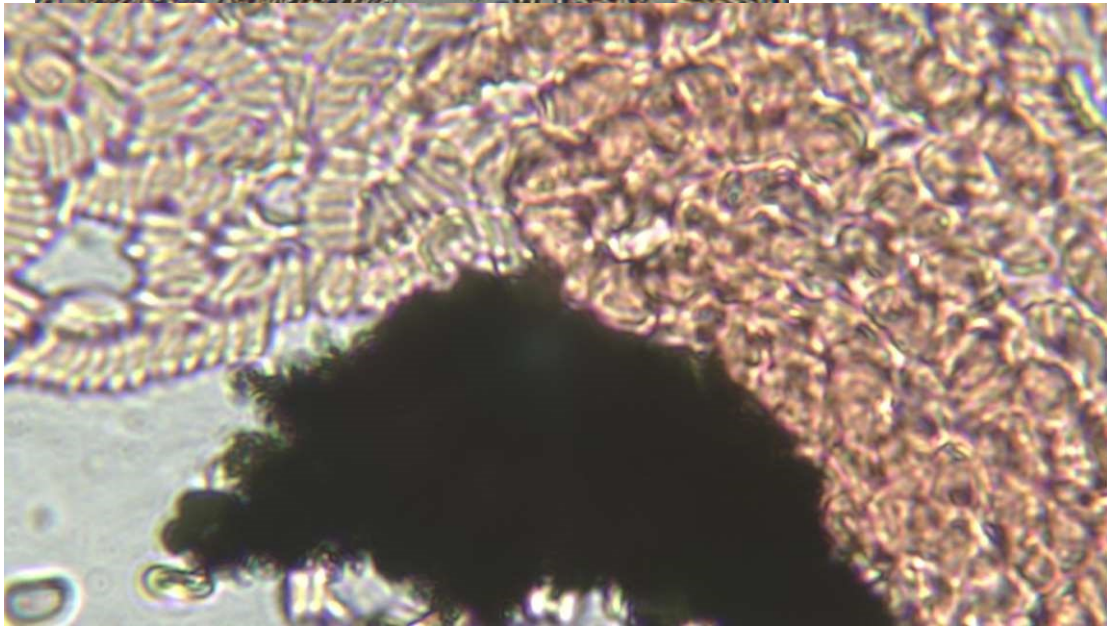
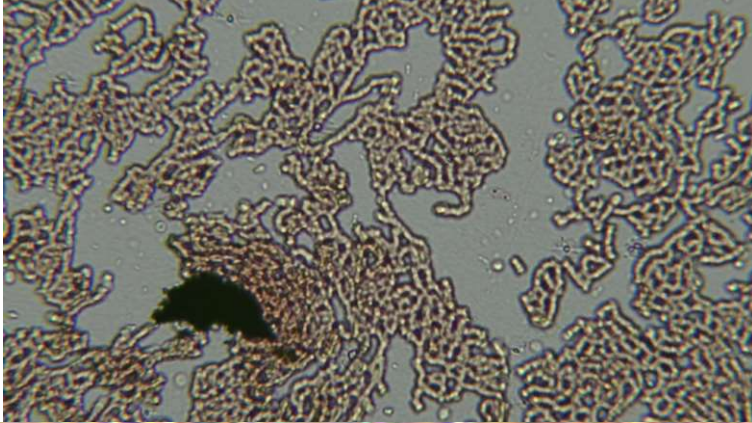
5. Severe rouleau, where the red blood cells form a chainlike string. All the vaccinated people have very tightly stacked red blood cells, a more serious form of rouleau suggestive of a patient with a chronic degenerative disease. Uric acid crystal. 1600 x magnification

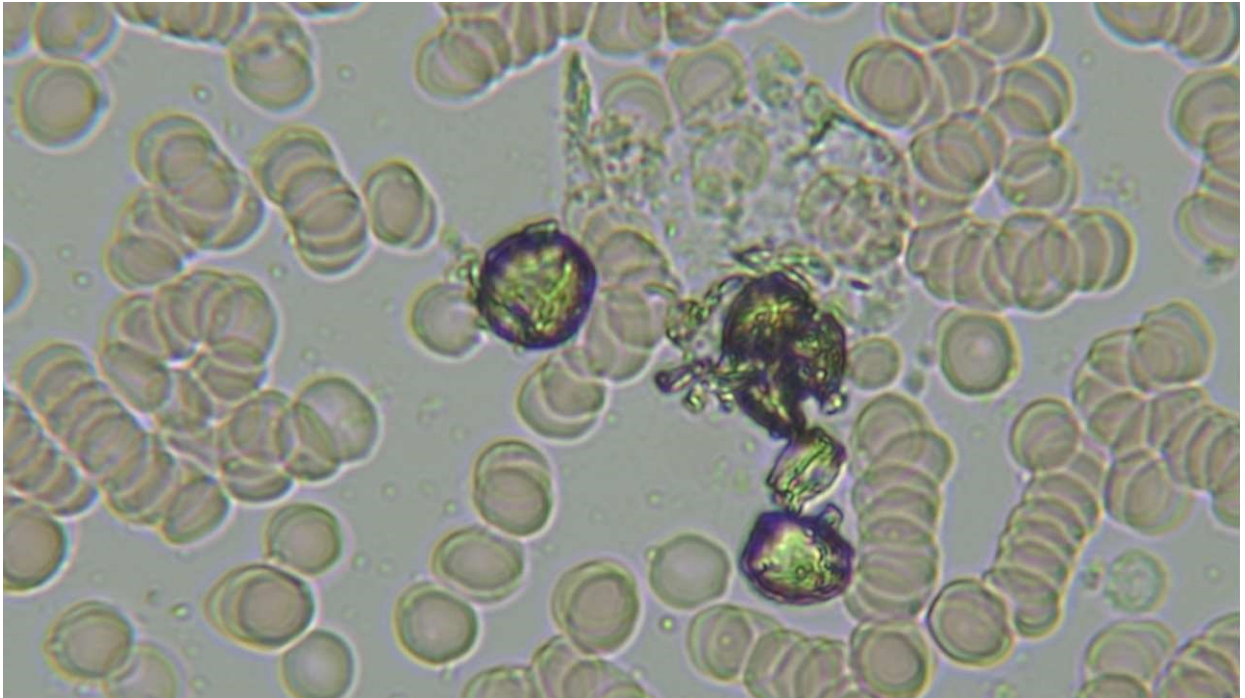


6. Severe rouleau, where the red blood cells form a chainlike string. Red blood cell aggregation . 800 x magnification.

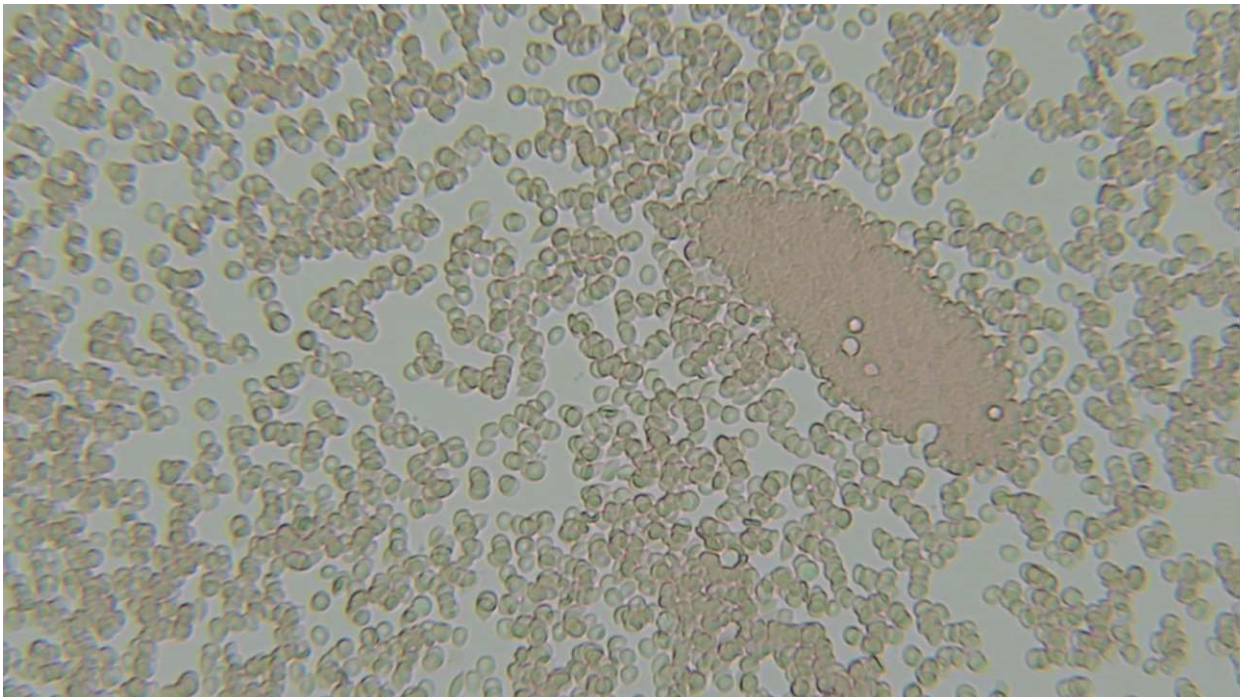


7. Severe rouleau, where the red blood cells form a chainlike string. All the vaccinated people have very tightly stacked red blood cells, a more serious form of rouleau suggestive of a patient with a chronic degenerative disease. Black matter. Nonviable WBC. 400 and 800 x magnification

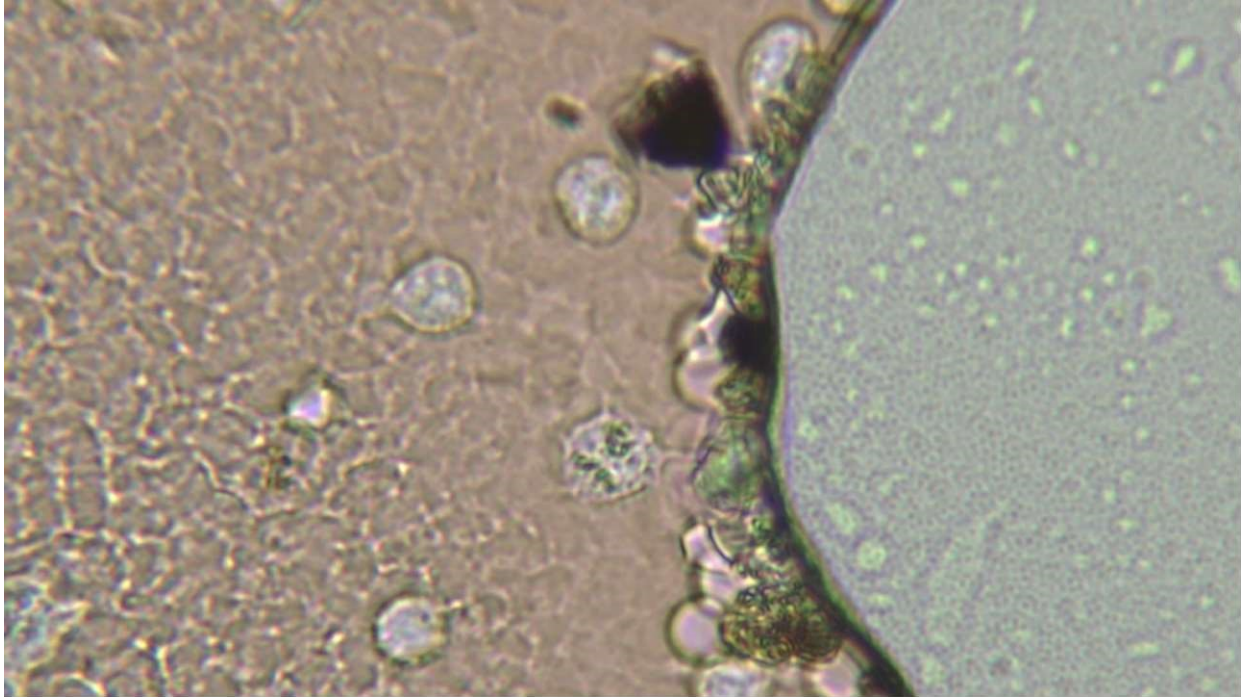




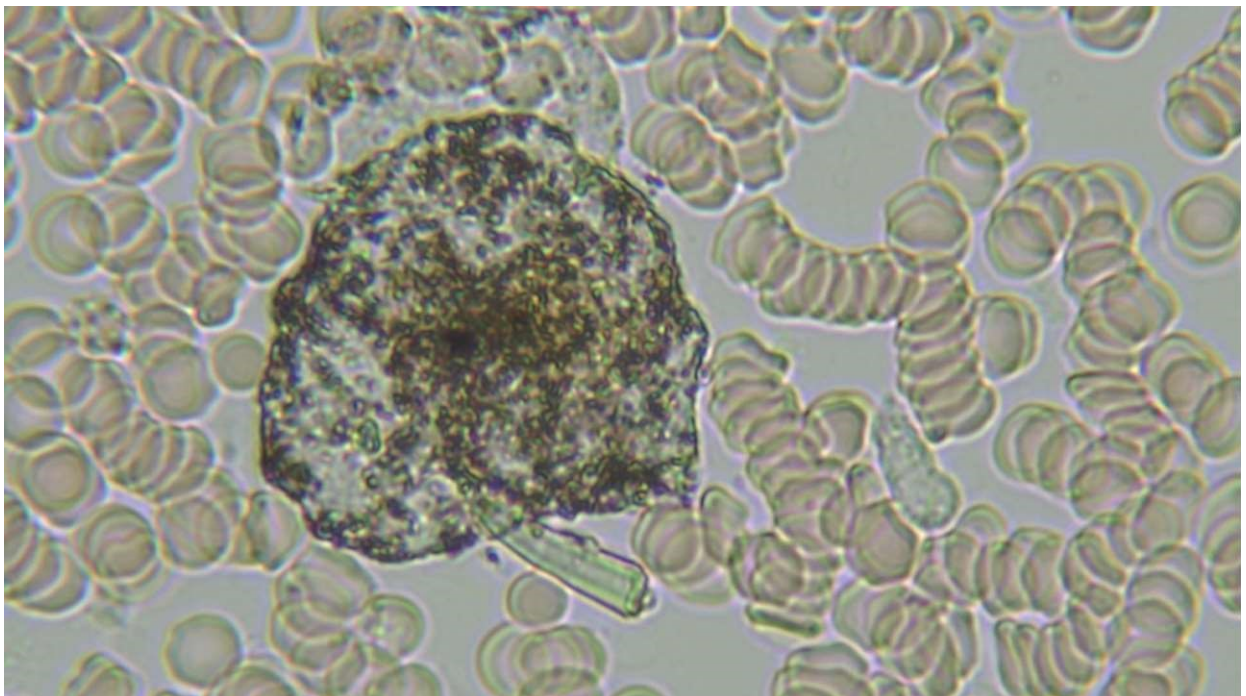
Unidentified particles done at 1600 x magnification. Rouleau. Protoplast



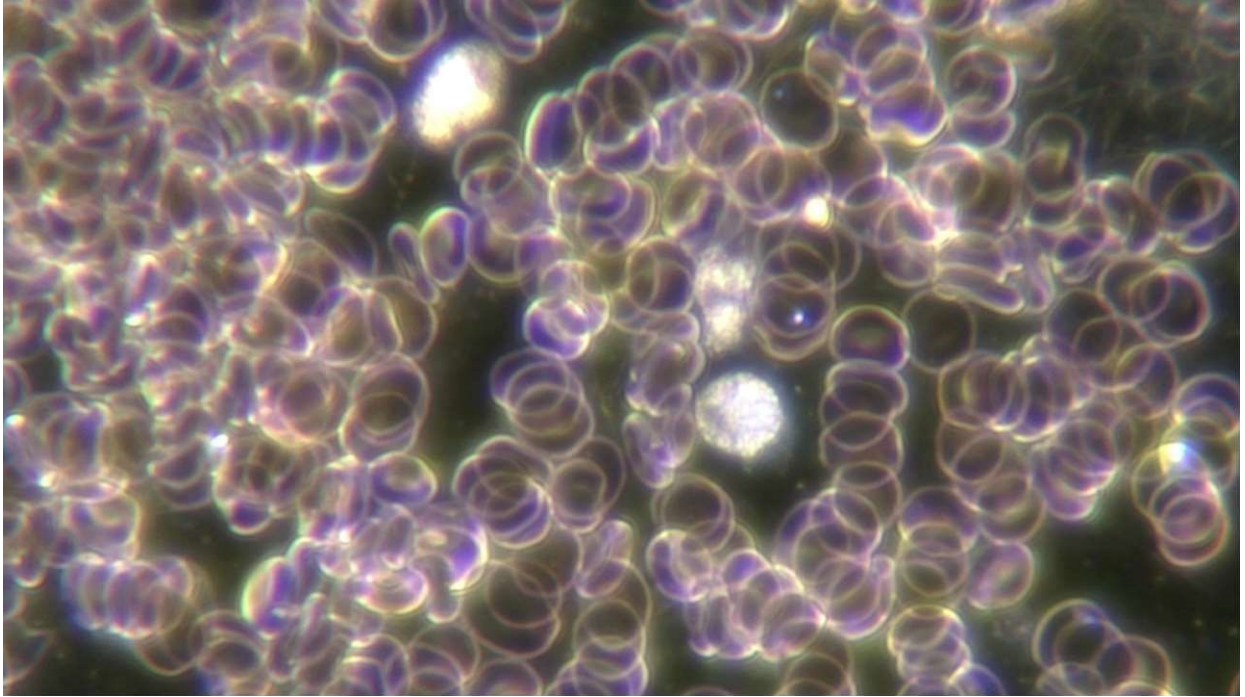
Red blood cell aggregation. 400 x magnification



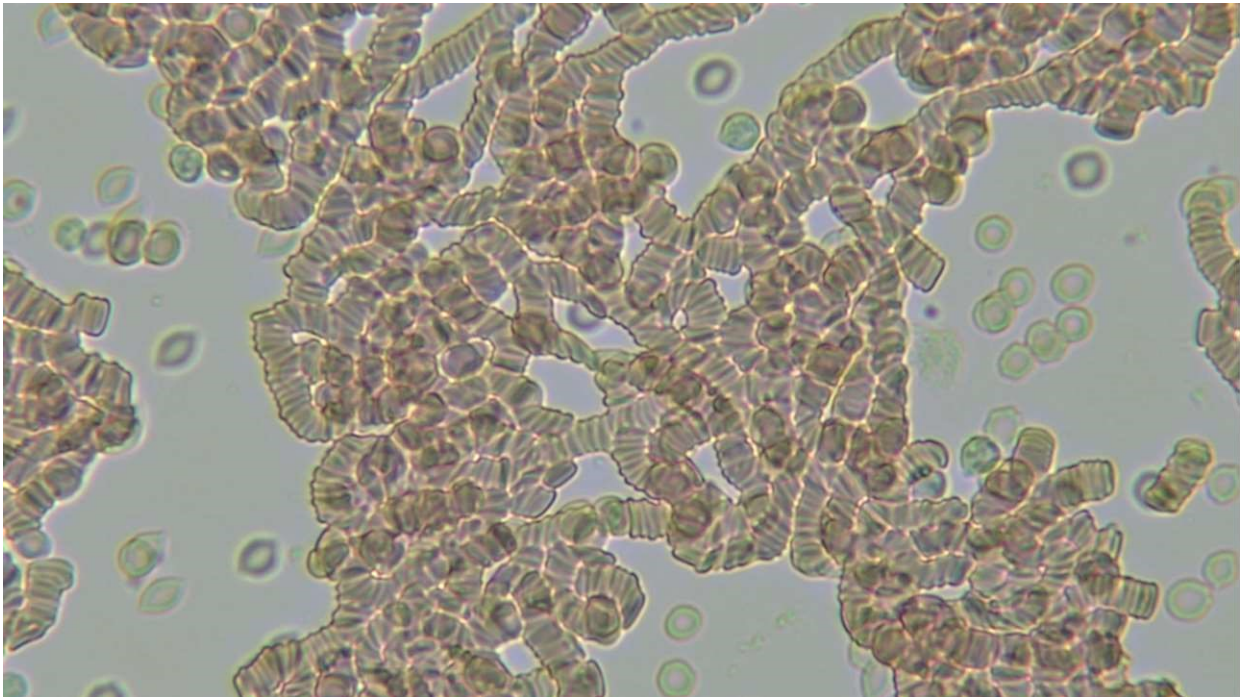
Red blood cell aggregation. Immature white blood cells unidentified black matter and crystals. 1600 x magnification



Protoplast and black matter. Atherosclerotic plaque 1600 x magnification

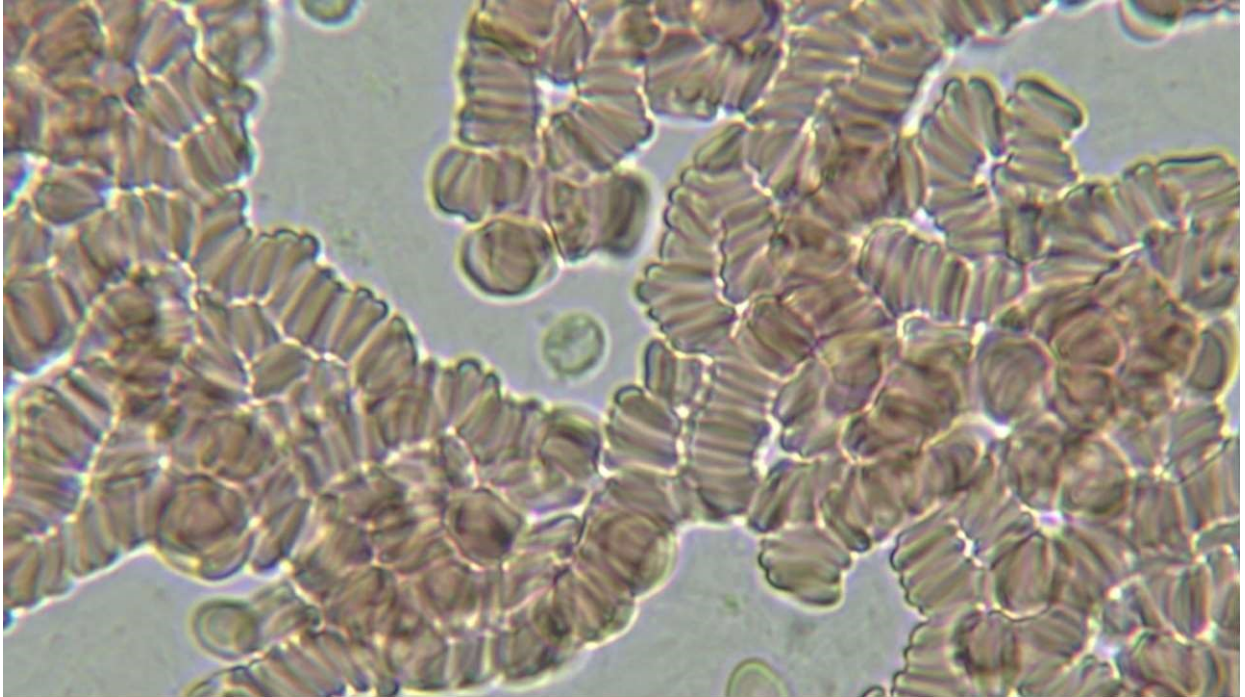


**Non-viable white blood cells. Mis formed red blood cells. 1600 x magnification
Stacking of red blood cells abnormally small white blood cells 800 x magnify.**





Dr Zandr  Botha (Ph D Alt. Med)
18 Wildebees Street
Rant en Dal
1751
Gauteng
South Africa
Practice No: LC-HPD083108
Office nr: 081 526 6005



Abnormally small white blood cells. Rouleau stacking 1600 x magnification



KIND REGARDS
DR ZANDRE BOTHA

011 660 5730 | 081 526 6005 | INFO@DRZANDREBOTH.COM
WWW.DRZANDREBOTH.COM
18 WILDEBEE ST. RANT-EN-DAL. KRUGERSDORP 1739
PRACTICE NUMBER LC-HPD083108